

RELATIONSHIP BETWEEN POST BOWEL RESECTION ILEO-ILEAL INTUSSUSCEPTION: SYSTEMATIC REVIEW

Yusuf Almalik Saputra^{1*}, Hery Poerwosusanta²

^{1*}Faculty of Medicine, University of Palangka Raya, Indonesia

²Pediatric Surgery Division, Department of Surgery, Lambung Mangkurat University/Ulin Hospital, Banjarmasin, Indonesia

***Corresponding Author:**

saputra.yusuf.almalik@gmail.com

Abstrak

Background: Intussusception is when the proximal segment of the intestine (intussusceptum) enters the distal segment (intussusciens) and when the opposite direction is known as retrograde intussusception.

The aim: This study aims to explain the incidence, mechanism, diagnostic tool, and treatment of ileo-ileal intussusception after intestinal resection.

Methods: This study can show that it meets all requirements by comparing itself to the standards the Preferred Reporting Items for Systematic Review and Meta-Analysis (PRISMA) 2020. Publications between 2013 and 2023 are considered. We excluded cut reviews and finished works.

Result: This study lists five eligible studies.

Conclusion: Surgical exploration is necessary to verify the diagnosis and exclude an underlying malignancy. However, there is no universal consensus regarding the indication for intraoperative reduction and the extent of bowel resection.

Katakunci: Intussusception, ileo-ileal, bowel resection.

INTRODUCTION

Pediatric surgeons often treat intussusception. Intussusception is more common in the small intestine and rarely involves isolated large intestine. The natural history of intussusception begins with a lead point, including lymphadenopathy, polyp, or cancer, which acts as focal traction pulling the proximal bowel into the peristaltic distal bowel. Symptoms arise from obstruction and continued ischemia of the affected segment, leading to necrosis and perforation.^{1,2} The cause is usually unknown in babies, whereas in adults, the starting point is often cancer.^{2,3} One of the neglected causes of post-operative intestinal obstruction is post-operative intestinal intussusception. 51.2% and 20.5% of post-operative intestinal intussusception occurred in the gastrointestinal tract and retroperitoneal tumour resection procedures, respectively.⁴ The study aims to describe the incidence, mechanism, diagnostic tool, and treatment of intussusception after intestinal resection.

METHODS

Protocol

This study complied with the requirements and its accurate conclusions by following the Preferred Reporting Items for Systematic Review and Meta-Analysis (PRISMA) 2020.

Criteria for Eligibility

This literature review aimed to explain, compare and contrast the incidence and mechanisms, and improve treatment of ileo-ileal intussusception after bowel resection. This study demonstrated and improved intussusception handling after intestinal resection. The study must meet the requirements: 1) Papers must be written in English, and the need to determine the best management of ileo-ileal intussusception after bowel resection. 2) Papers published after 2013. Research that is not allowed include editorials, no DOI submissions, published review articles, and published identical journal.

Search Strategy

This study used "intussusception after bowel resection"; "ileo-ileal intussusception" as a keyword for inclusion in a systematic review using the SagePub and PubMed databases by words: ("intussusception" [MeSH Subheading] OR "intussusception" [All Fields] OR "ileo-ileal intussusception" [All Fields]) AND ("bochdalek" [All Fields] OR "bochdalek s" [All Fields]) AND ("post bowel resection" [MeSH Terms] OR ("bowel resection" [All Fields]) OR ("complication of bowel resection" [All Fields]) AND "incidence of intussusception" [All Fields]) OR ("prevalence of intussusception" [All Fields]) OR ("intussusception mechanism" [All Fields]) OR ("mechanism of intussusception" [All Fields]) AND "treatment of intussusception" [All Fields]) AND ("treatment"[All Fields]) AND (clinicaltrial[Filter])) used in searching the literature.

Data Retrieval

The authors examined the studies by reading the abstracts and titles to determine inclusion criteria. Articles in English that cannot be viewed elsewhere are included in the conclusion criteria.

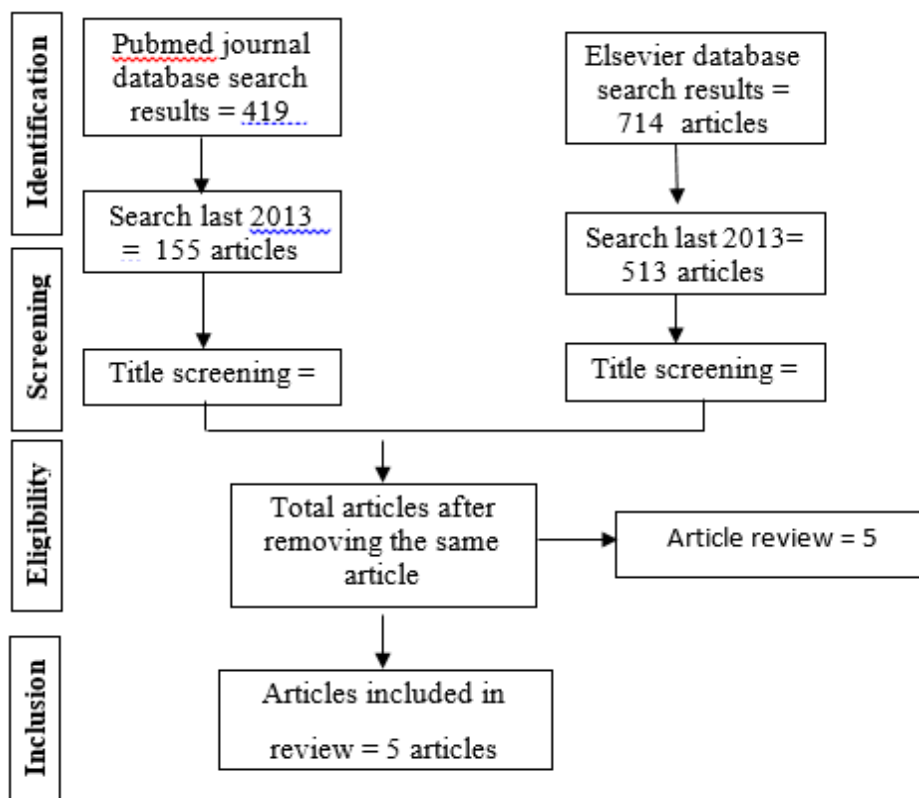


Figure 1. Article search flowchart

Quality Assessment and Data Synthesis

Each author studies publication titles and abstracts before deciding to explore. Articles that meet the review requirements and the purpose of writing will be reviewed based on the findings of the evaluation and discussion.

RESULT

Our search on the PubMed database yielded 419 articles and 714 on Elsevier. Search results conducted since 2013 yielded 155 articles in PubMed and 513 in Elsevier. We compiled seven articles and the final five eligible studies.

Abukhalaf et al. (2019)⁴ reported 4 cases, 3 cases of ileoileal and 1 ileocolic POI after bowel manipulation. 75% of patients came the first two weeks, and 1 patient after two months after the revision of the prolapsed colostomy. All patients underwent laparotomy manual reduction with or without bowel resection. All patients had no post-operative complications. Because of the POI rarity, there were diagnostic difficulties. A diagnosis of intussusception is unthinkable because of rare cases. Patients came with obstructive complaints, abdominal distention, and bilious vomiting. The cause is a coincidental idiopathic suspected of excessive bowel manipulation, altered peristalsis, electrolyte imbalance, medications (anaesthetics and opioids), no identified lead points, and prolonged adynamic ileus. The pre-operative diagnosis was based on clinical signs of intestinal obstruction and abdominal upright radiology.

Guerci et al. (2022)¹¹ Rare adult intussusception is usually 90% due to the starting point. The pre-operative diagnosis was based on clinical signs of intestinal obstruction, and abdominal plain radiography showed an air-fluid level in the mesogastrium. Sonogram showed a mass, and an abdominal CT showed wall thickening, typical target sign, bull eye, sausage shape, and concentric double-ring sign for ileo-ileal intussusception. Adult intussusception generally requires bowel resection because of the potential for malignancy.

Tarchouli and Ali (2021)¹² showed 26 cases, 16 males and ten females. The mean age was 45 years (range 21–70). The pre-operative diagnosis was made in 21/26 (81%) patients using clinical features, ultrasound, and CT scan. Five intussusceptions were found in exploratory laparotomy for intestinal obstruction. There were 19 (73%) cases in the small intestine and 7 (27%) in the colon. Surgical exploration is the treatment of choice, and intestinal resection with immediate anastomosis was the technique of choice. One patient underwent a stoma for secondary peritonitis to intestinal perforation. No idiopathic intussusception was detected, and malignancy was aetiology in 9 (35%) cases.

Author	Origin	Method	Sample Size	Result
Abukhalaf et al., 2019 ⁴	Palestine	Case Series Retrospective study	4 Cases	This study reported four patients. One came two months after the revision of the prolapsed colostomy and generally came the first two weeks. All patients were managed with uncomplicated manual reduction. The pre-operative diagnosis was based on clinical signs of intestinal obstruction and abdominal upright radiology.
Guerci et al., 2022 ¹¹	Italy	Case Report	1 Case	Adult intussusception is less common than children, with 90% accompanied by a lead point. Pre-operative diagnosis based on clinical signs of intestinal obstruction, sonogram, and CT scan. Adult intussusception should be bowel resection because of the risk of malignancy.
Tarchouli & Ali, 2021 ¹²	Morocco	A retrospective review	26 Cases	Adult intussusception is different from children's. In adults, a lead point causes it, while children are idiopathic. Pre-operative diagnosis based on clinical signs of intestinal obstruction, sonogram, and CT scan has an accuracy of 81%. CT scanning improves accuracy in adult intussusception.
Kim, 2021 ¹³	Korea	A Retrospective Review from a Single Institution	28 Patients	Adult small bowel intussusception (SBI) has a higher lead point than colonic intussusception (CI), and the lead points are benign and malignant. En bloc resection is the first treatment for adult intussusception (AI).
Marinis et al., 2023 ⁸	Dubai	Case Report and Literature Review	1 Case	Adult ileoileal intussusception presents a surgical challenge and is very rare accounts less than 1%. Surgical intervention is required because adult intussusception is usually linked to malignant organic lesions. The affected bowel segment must typically be surgically removed as part of the treatment. If the affected segment is still viable or no indication of cancer exists, a reduction can be tried in cases with small bowel intussusceptions.

Kim et al. (2021)¹³ showed pediatric intussusception is idiopathic, and the lead point is present in 25% of cases, whereas adults are present in 70-90% of cases. Pediatric intussusception includes abdominal emergencies in children < 2 years.

Adult intussusception occurs in 5% of cases, and the clinical manifestations are non-specific, so the diagnosis is often delayed. The mean age of occurrence was 51 years (IQR, 40-70 years). The ileocolic type occurs in 36% of cases and ileoileal in 32%. Incidence is more women (64%) than men (36%).

Marinis *et al.* (2023)⁸ demonstrated adult ileoileal intussusception as a surgical challenge with 1-5% incidence. Four % is idiopathic, and 16% cause organic lesion. The pathognomonic clinical picture of adult intussusception is atypical, and the diagnosis is often missed, in contrast to children with typical and subacute symptoms. Abdominal CT is the most accurate imaging method for identifying intussusception and detecting a lead point. Surgical intervention is necessary because adult intussusception is associated with malignant lesions. The affected bowel segment generally has to be resected. The affected small bowel segment is still, and no indication of cancer can be maintained.

DISCUSSION

Post-operative intestinal intussusception is a rare variant case. Post-operative intestinal intussusception is reported in non and abdominal surgeries. Late diagnosis can lead to ischemia and necrosis and increases morbidity and mortality, providing early diagnosis and prompt treatment as a lifesaver.⁴ The incidence is 0.01-0.25%, with a higher incidence rate in pancreatic resection of 2.1% and stomach tumor resection of 1.2%. A higher incidence rate is in males and those with mental disorders. Post-operative intestinal intussusception is not only a complication of pediatric procedures but also in adults, although less frequently.⁴

In children, the clinical presentation is often acute and easily recognized by the classic triad of abdominal pain, rectal bleeding, and a palpable abdominal mass. Without surgical intervention, most cases can be successfully treated with hydrostatic or pneumatic reduction. In contrast, intussusception in adults is a rare disorder representing only 1% of intestinal obstructions and nearly 5% of all cases of intussusception. Unfortunately, clinical signs are often non-specific and make diagnosis difficult. Computed tomography (CT) for abdominal complaints has significantly increased the detection of adult intussusception, especially in the transient and asymptomatic form. The characteristic gut-within-the-gut appearance, often containing mesenteric fat and blood vessels, is pathognomonic. Pathological lead points cause most adult intussusceptions with approximately 60% being malignancies.¹²

CONCLUSION

Post-operative intestinal intussusception is a rare variant in children and adults. Surgical exploration is necessary to verify the diagnosis and exclude an underlying malignancy. If non-vital intestinal is found and suspicion of malignancy, resection is mandatory.

REFERENCE

- [1]. Mizell, Jason S. Approaches and Treatment of Intussusception, Volvulus, Rectal Prolapse A. Functional Disorders of the Colon, Rectum, and Anus. *Clin Colon Rectal Surg.* 2017;30(1):003–4.
- [2]. Shobhit J, Michelle H. Child Intussusception. *StatPearls* [Internet]. 2023;1–7. Available from: <https://www.ncbi.nlm.nih.gov/books/NBK431078/>
- [3]. Boi-Dsane NAA, Seidu AS, Owusu SA. Post-operative ileo-ileal intussusception one week after hemicolectomy for ileo-colic intussusception. *J Pediatr Surg Case Reports* [Internet]. 2023;88(September 2022):102506. Available from: <https://doi.org/10.1016/j.epsc.2022.102506>
- [4]. Abukhalaf SA, Alzughayyar TZ, Baniowda MA, Abukarsh R, Ghazzawi I, Novotny NM, et al. Post-operative intestinal intussusception in children, an easily missed culprit of post-operative intestinal obstruction: Case series and literature review. *Int J Surg Case Rep* [Internet]. 2019;60:336–9. Available from: <https://doi.org/10.1016/j.ijscr.2019.06.057>
- [5]. Xia F, Sun Z, Wu JH, Zou Y. Intussusception after reconstruction following gastrectomy for gastric cancer. *World J Surg Oncol* [Internet]. 2021;19(1):4–9. Available from: <https://doi.org/10.1186/s12957-021-02456-3>
- [6]. Hussain AS, Warriar R, Papaconstantinou HT. Small Bowel Intussusception Causing a Post-operative Bowel Obstruction Following Laparoscopic Low Anterior Resection in an Adult. *Baylor Univ Med Cent Proc.* 2014;27(2):128–30.
- [7]. Bohrer SP. Intussusception in adults. *AJR Am J Roentgenol.* 1986;147(1):216.
- [8]. Marinis A, Yiallourou A, Samanides L, Dafnios N, Anastasopoulos G, Vassiliou I, Theodosopoulos T. Intussusception of the bowel in adults: a review. *World journal of gastroenterology: WJG.* 2009 Jan 1;15(4):407.
- [9]. Monazzami M, Atqiaee K, Dehghanian P, Shaman Zahroodi H. The Ileoileal intussusception due to a tubular duplication in a child: A case report. *Clin Case Reports.* 2022;10(12):3–6.
- [10]. Uyulmaz S, Zünd M, Caspar U, Diebold J, Slankamenac K. Ileoileal intussusception in unspecific recurrent abdominal pain in adult: A case report. *SAGE Open Med Case Reports.* 2018;6:2050313X1879281.
- [11]. Guerci C, Colombo F, Goi G, Zerbi P, Pirrò B, Danelli P. Case Report: Ileo-Ileal Intussusception Secondary to Inflammatory Fibroid Polyp: A Rare Cause of Intestinal Obstruction. *Front Surg.* 2022;9(April):1–7.
- [12]. Tarchouli M, Ait Ali A. Adult Intussusception: An Uncommon Condition and Challenging Management. *Visc Med.* 2021;37(2):120–7.
- [13]. Kim KH. Intussusception in adults: A retrospective review from a single institution. *Open Access Emerg Med.* 2021;13:233–7.