

IMAGING OF APPENDICITIS: A SYSTEMATIC REVIEW

Bella Sugih Laksono

Nurhayati General Hospital, Garut, Indonesia

Corresponding Author :
bellasugih@gmail.com

ABSTRACT

Introduction: *Delayed diagnosis and treatment might cause gangrene perforation and diffuse peritonitis. This makes radiological exams easy and sensitive and specific. The radiological examination, which includes ultrasound and picture, can be done quickly. In addition to difficult exams like CT scans and barium enemas, these are done.*

The aim: *This study review imaging for appendicitis.*

Methods: *For this systematic review, publications that were published from 2012 to 2023 were taken into account during the search process. This was achieved through the utilization of numerous online reference sources, such as Pubmed and SagePub. The decision was made to exclude review articles, previously published works, and incomplete works.*

Result: *We found seven studies related to the ability of radiological examination in the diagnosis of appendicitis. The research discusses CT scans and ultrasonography.*

Conclusion: *There are several examinations that can be done, for example US, plain radiology and CT scan. An ultrasound examination is an examination that can be carried out quickly and with sufficient accuracy to determine whether a person can be diagnosed as a patient with appendicitis.*

Keyword: *Appendicitis; Imaging; Plain radiography; Ultrasound*

INTRODUCTION

Surgical intervention is required immediately in order to prevent major complications from occurring in cases of appendicitis, which is the most common emergency case involving abdominal surgery. The patient's morbidity and death rate will increase if the appendicitis is not treated in a timely manner.¹ Appendicitis is an inflammatory process or inflammation of the vermiform appendix organ or also known as the appendix. Acute appendicitis is a medical emergency and is one of the most frequently encountered acute abdominal cases.²

Appendicitis usually strikes between 10 and 20. We have 1.4 men to 1 women. According to US studies, men have an 8.6% lifetime risk of appendicitis and women 6.7%. Acute appendicitis has been linked to colorectal cancer. Colorectal cancer was found in 2.9% of appendicitis patients and 0.1% of non-appendicitis patients.³ A UK survey found that 42,000 to 47,000 appendix surgeries were conducted annually between 2007 and 2012. Appendicitis complications occur 16.5%–24.4% of the time. Appendicitis usually strikes between 10 and 20. We have 1.4 men to 1 women. According to US studies, men have an 8.6% lifetime risk of appendicitis and women 6.7%.^{3,4}

Acute appendicitis has been linked to colorectal cancer. Colorectal cancer was found in 2.9% of appendicitis patients and 0.1% of non-appendicitis patients. A UK survey found that 42,000 to 47,000 appendix surgeries were conducted annually between 2007 and 2012. Appendicitis complications occur 16.5%–24.4% of the time. For easy treatment, acute appendicitis must be diagnosed quickly and precisely. However, delayed identification and treatment might induce gangrene perforation and diffuse peritonitis. Due to the reliability of positive values, needless appendectomies (20-30%) are permissible.⁵⁻⁷

Delaying diagnosis and treatment can result in gangrene perforation and diffuse peritonitis. This makes radiological examinations easy to carry out with good sensitivity and specificity.⁸ The radiological examination is a modality that may be utilized in a short amount of time, providing options such as the ultrasound examination and the plain photo examination. In addition to additional difficult examinations such as computed tomography scans and barium enemas, these tests are also performed.⁹ The utilization of imaging diagnostics for appendicitis is included within the scope of this inquiry.

METHODS

In accordance with PRISMA 2020, all data acquisition, processing, and reporting requirements were fulfilled. The imposition of additional restrictions was impacted by a multitude of influencing factors. An analysis of the usage of imaging techniques in the diagnosis of appendicitis. As per the principal findings of the study, all written materials pertaining to appendicitis imaging must be composed in the English language. The current systematic review assessed scholarly articles that were published subsequent to 2013 and fulfilled the pre-established criteria for inclusion in the research. Editorials, entries lacking a DOI, previously published book reviews, duplicate journal articles that are excessively lengthy, and such materials will be excluded from the compilation.

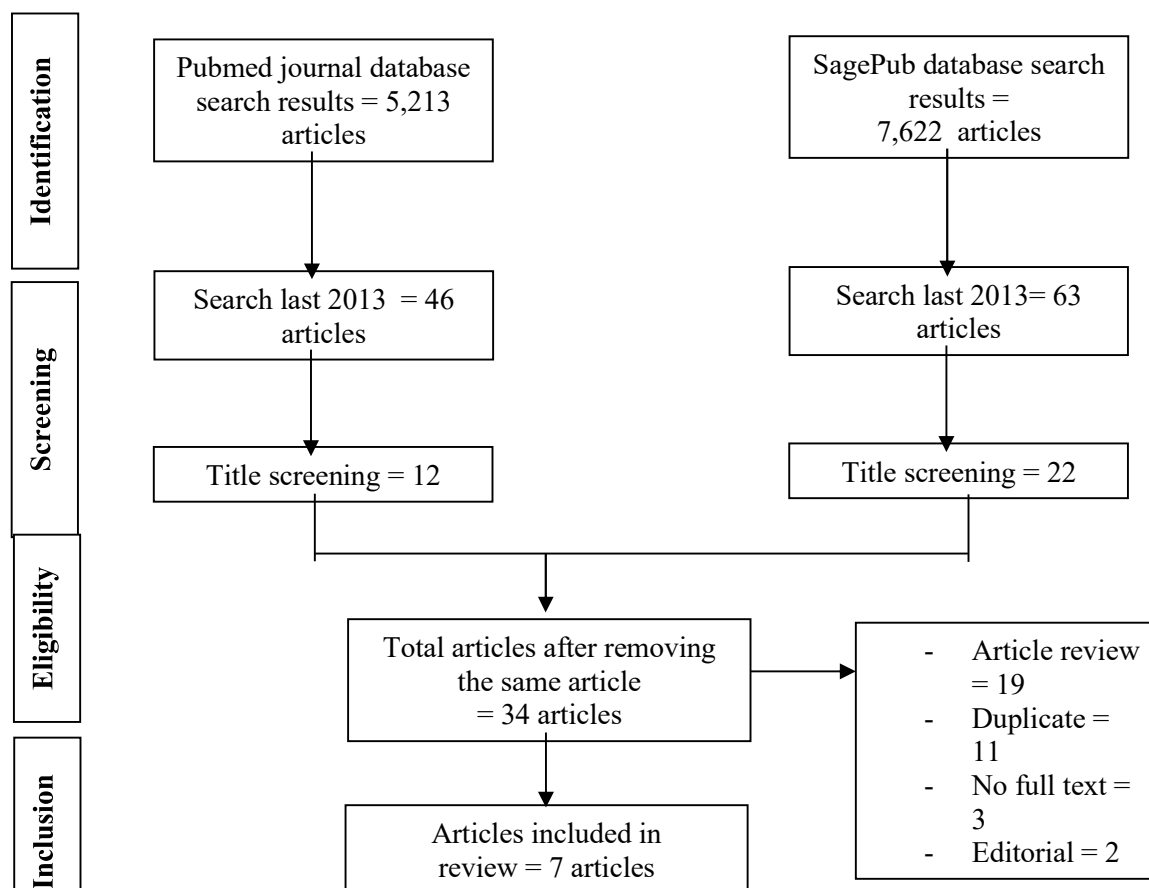


Figure 1. Article search flowchart

The search for studies to be included in the systematic review was carried out from December, 12th 2023 using the PubMed and SagePub databases by inputting the words: “imaging” and “appendicitis”. Where (*"image"[All Fields] OR "image s"[All Fields] OR "imaged"[All Fields] OR "imager"[All Fields] OR "imager s"[All Fields] OR "imagers"[All Fields] OR "images"[All Fields] OR "imaging"[All Fields] OR "imaging s"[All Fields] OR "imagings"[All Fields] AND ("appendical"[All Fields] OR "appendicitis"[MeSH Terms] OR "appendicitis"[All Fields])*) is used as search keywords.

The titles and abstracts of the studies similarly impacted their acceptability. As a consequence, they are compelled to depend on historical archives. In light of the consistent nature of research findings, it is mandatory to submit unpublished English papers. The inclusion criteria were rigorously adhered to throughout the process of selecting studies for the systematic review. By doing so, the search is restricted to solely those results that satisfy the predetermined criteria. The subsequent sections delineate the assessment methodology. An exhaustive examination was conducted of a multitude of variables, encompassing authors, dates of publication, geographic locations, activities, and motivations.

Following the documentation of the search results by EndNote, the database initiated the process of identifying and eliminating duplicate articles. Prior to the composition of this article, the titles and abstracts of each paper were assessed by two individuals. Prior to making determinations regarding coverage, every author performs an exhaustive evaluation of relevant abstracts and article titles. Every paper that meets the pre-established standards for assessment will undergo a thorough and meticulous examination. After concluding the investigation, we shall reassess any relevant scientific publications that we might have neglected during our initial examination. It was justifiable to exclude extraneous research in favor of pertinent research.

RESULT

Kim, et al (2019)¹⁰ showed the expense of a lower level of specificity, the pooled sensitivity of the presence of any of the ten CT features was found to be higher than that of the gestalt assessment methodology. It is possible to apply the any-of-10-features criterion in order to reduce the risks of treatment failure that are linked with a false-negative diagnosis of complication. This criterion can be utilized for the cautious selection of patients who should get nonoperative treatment for appendicitis.

Bourcier, et al (2018)¹¹ conducted a study with abdominal pain patients. They showed the diagnosed cases were: appendicitis (53), non-specific abdominal pain (48), lymphadenitis (22), ileitis (11), complicated ovarian cysts (7), neoplasias (5), inflammatory or infectious colitis (5), inguinal herniations (3), bowel obstructions (2), and salpingitis (2). The accuracy of ultrasound diagnoses was 0.89 (95% confidence interval [CI] = 0.84-0.94) versus 0.70 (95% CI = 0.57-0.82) for diagnoses based on clinical-laboratory examination only (p < 0.001). Besides, ultrasound allows an accurate diagnosis of a surgical pathology in 89% of cases, which is more efficient than the clinical-laboratory examination.

Elbanna, et al (2018)¹² conducted a study with 209 patients. The sensitivity of 40-kV virtual monoenergetic imaging was 100% (44/44); specificity, 81.2% (134/165); PPV, 58.7% (44/75); NPV, 100% (134/134); accuracy, 85.2%; and interobserver agreement, 0.99. With high sensitivity and specificity, dual-energy computed tomography (CT) that incorporates virtual monoenergetic and iodine overlay imaging is an accurate method for verifying and rejecting the presence of gangrenous appendicitis in cases where appendicitis is suspected.

Corson-Knowles, et al (2018)¹³ showed the rate of appendicitis was 36.8% in those with moderate to high pre-test probability. Clinical ultrasound (CUS) were recorded by 33 different emergency physicians (EP). The sensitivity, specificity, and positive and negative likelihood ratios of EP-performed CUS in patients with moderate to high pre-test probability were 42.8% (95% confidence interval [CI] = 25-62.5%), 97.9% (95% CI = 87.5-99.8%), 20.7 (95% CI = 2.8-149.9) and 0.58 (95% CI = 0.42-0.8), respectively. The 16 false negative scans were all interpreted as indeterminate. There was one false positive CUS diagnosis; however, the sonographer reported low confidence of 2/10.

Table 1. The literature include in this study

Author	Origin	Method	Sample	Modality	Conclusion
Kim, 2019 ¹⁰	Republic of Korea	Retrospective study	100 patients with suspected appendicitis	CT scan	The pooled sensitivity of the presence of any of 10 CT features was higher than that of gestalt assessment (92% vs 64%; difference, 28% [95% CI, 10-46%]; p < 0.001), although the pooled specificity was lower (43% vs 76%; difference, -33% [95% CI, -48% to -17%]; p < 0.001).
Bourcier, 2018 ¹¹	France	Prospective cohort study	158 patients	Ultrasound	Appendicitis (53), non-specific abdominal discomfort (48), lymphadenitis (22), ileitis

			abdominal pain		(11), complex ovarian cysts (7), neoplasias (5), inflammatory or infectious colitis (5), inguinal herniations (3), bowel obstructions (2), and salpingitis (2) were diagnosed. Ultrasound diagnosis accuracy was 0.89 (95% CI 0.84-0.94) compared to 0.70 (95% CI 0.57-0.82) for clinical-laboratory examination-only diagnoses (p < 0.001).
Elbanna, 2018 ¹²	Canada	Retrospective study	209 patients with a pathologic diagnosis of appendicitis	CT scan	The sensitivity of 40-kV virtual monoenergetic imaging was 100% (44/44); specificity, 81.2% (134/165); PPV, 58.7% (44/75); NPV, 100% (134/134); accuracy, 85.2%; and interobserver agreement, 0.99. The corresponding values for the iodine overlay imaging datasets were 100% (44/44), 80.0% (132/165), 57.1% (44/77), 100% (132/132), 84.2%, and 0.99 and for 120-kV simulated imaging were 22.7% (10/44), 96.4% (159/165), 62.5% (10/16), 82.4% (159/193), 77.5%, and 0.93.
Corson-Knowles, 2018 ¹³	United State	Prospective cohort study	105 patients	Ultrasound	Moderate to high pre-test chance was 36.8% appendicitis. 33 CUS EPs. EP-performed CUS exhibited 42.8% sensitivity, 97.9% specificity, 20.7 sensitivity, and 0.58 sensitivity in moderate to high pre-test likelihood patients. All 16 false negatives were unsure. One CUS diagnosis was false positive, but sonographer reported 2/10 confidence.
Gungor, 2017 ¹⁴	Turkey	Prospective cohort study	264 patients suspected appendicitis	Bedside ultrasound	The sensitivity, specificity, PLR, and NLR of US examinations were 92.3% (95% confidence interval [CI] = 87.2%-95.8%), 95.8% (89.5%-98.8%), 21.9 (8.4-57.2), and 0.08 (0.05-0.1) for POCUS and 76.9% (69.8-83%), 97.8% (84.9-99.7%), 36.4 (9.25-144.3), and 0.24 (0.18-0.31) for RADUS
Mallin, 2015 ¹⁵	United State	Prospective cohort study	97 cases of suspected appendicitis	Bedside ultrasound	There was 1 false-positive result, yielding a sensitivity of 67.65% (95% confidence limits, 49.5%-82.6%) and a specificity of 98.41% (95% confidence limits, 91.4%-99.7%).
Tan, 2015 ¹⁶	Singapore	Prospective cohort study	350 consecutive patients with suspected appendicitis	CT scan	Positive likelihood ratio of disease was significantly greater than 1 only in patients with an AS of 4 and above. An AS of 7 and above in males and 9 and above in females has a positive likelihood ratio comparable to that of CT scan.

Gungor, et al (2017)¹⁴ conducted a study comparing point-of-care US (POCUS) and radiology-performed US (RADUS). They showed 92.3% (95% confidence interval [CI] = 87.2%-95.8%), 95.8% (89.5%-98.8%), 21.9 (8.4-57.2), and 0.08 (0.05-0.1) for POCUS, and 76.9% (69.8-83%), 97.8% (84.9-99.7%), 36.4 (9.25-144.3), and 0.24 (0.18-0.31) for RADUS, were the sensitivity, specificity, PLR, and NLR of US examinations, respectively. Performing point-of-care ultrasonography in the emergency department (ED) for diagnosing acute appendicitis (AA) yields good sensitivity and specificity. This practice significantly influences the clinical decision-making process of emergency physicians (EPs).

Mallin, et al (2015)¹⁵ were performed US on 97 adult cases susp appendicitis. Twenty-four BUS showed acute appendicitis, while eleven were nondiagnostic. Pathology confirmed appendicitis in 23 of 24 positive ultrasounds. Due to one false-positive

result, specificity was 98.41% (95% CI = 91.4%-99.7%) and sensitivity was 67.65%. Tan, et al (2015)¹⁶ examined 350 consecutive appendicitis suspects with CT scans. The positive likelihood ratio of disease was substantially more than 1 only in AS 4 and above individuals. AS of 7 or higher in males and 9 or higher in females has a favorable likelihood ratio like CT scan.

DISCUSSION

The usual appendix length is 8-10 cm (2-20 cm). The normal appendix has five layers: the mucosal surface and lumen, the hypoechoic mucosal layer, the submucosal layer, the muscularis propria layer, and the serosal layer. Normal appendices have an inner hypoechoic band without folds, distinguishing them from other intestinal structures. Normal appendixes are compressible tubular structures with an organ-free apex. The greatest outside diameter of a typical appendix is 6 mm. Gas, excrement, and fluid in the intraluminal area can extend this outer diameter.¹⁷

Plain Radiology

Plain radiology is generic, expensive, and sometimes deceptive. In <5%, an opaque fecalith may not be visible in the right lower quadrant. Simple abdominal radiography can rule out other conditions. In acute appendicitis, the intestine has an irregular "gas pattern" that is not identifiable. Fecaliths may confirm the diagnosis.¹⁸ Local air fluid level, right lower quadrant soft tissue density, psoas line shadow alterations, and free air (rare) if perforation occurs. Except for perforation, intestinal obstruction, and urinary tract calculus, plain radiographs are not advised. Plain abdominal radiography is not required for acute abdominal pain evaluation.^{18,19}

A barium enema is a diagnostic procedure in which barium is introduced into the colon via the anus for X-ray imaging. The use of barium enema is not recommended in cases of suspected acute appendicitis due to the potential risk of contrast entering the abdominal cavity and spreading bacteria, as there may be a microperforation present. The use of barium enema is recommended for cases of chronic appendicitis. An appendicogram is conducted by orally administering a diluted solution of fine powdered BaSO₄ contrast, with a ratio of 1:3, approximately 8-10 hours before for children and 10-12 hours before for adults.^{18,19}

A good result of this examination is indicated by the presence of a non-filling appendix with an indented cecum, which suggests the presence of chronic appendicitis. This signifies the existence of inflammation near the cecum. Partial filling, resulting in false negative results, was observed in 10% of cases. The routine use of barium enema for examining individuals suspected of acute appendicitis has been discontinued.^{18,19}

Ultrasound

In suspected acute appendicitis patients, ultrasonography is affordable, widely available, and accurate. However, histological confirmation after appendectomy is still the gold standard for appendicitis diagnosis. Graded compression ultrasonography can diagnose acute appendicitis with 44–100% sensitivity and 47–99% specificity. Operator inexperience, increased intestinal gas, obesity, anatomical variations, and restrictions in examining the patient with previous laparotomy cause this.^{6,7} Ultrasound is non-invasive, fast, radiation-free, and can diagnose various stomach discomfort reasons, especially in women of childbearing age.²⁰

Ultrasonography should be the first imaging examination for pregnant women and children because radiation exposure is harmful. Appendicitis can be diagnosed with 91% sensitivity, 97% specificity, 91% positive predictive value, and 94% negative predictive value with ultrasonography.²⁰ Adult acute appendicitis should be diagnosed by ultrasonography initially, according to research. At surgery, 71 of 79 patients had positive ultrasound results and 21 had positive CT scan results. Thirty-nine individuals with normal CT scans recovered without surgery. This procedure had 100% sensitivity and 86% specificity.¹⁵

Ultrasound can accurately diagnose acute appendicitis without delaying treatment. Although ultrasound is less accurate than CT scans, it can be utilized as the principal imaging modality and avoids radiation. Emergency room patients with suspected acute appendicitis may benefit from a bedside-bed ultrasonography. Bedside bed ultrasonography had 67.65% sensitivity and 98.41% specificity in one research. Ultrasound relies on operator vision and experience, a drawback. Clinically suspected acute appendicitis patients are referred to grading-compression ultrasound initially.¹⁵

CT scan

A CT scan is very useful in patients who are suspected of having an inflammatory process in the abdomen and whose symptoms are not typical for appendicitis. A normal appendix will show a thin tubular structure in the right lower quadrant that can become opaque with contrast. Appendicoliths appear as ring-shaped homogenous calcifications (halo sign), and are seen in 25% of the population. Acute appendicitis can be diagnosed based on CT-Scan if an abnormal appendix is found with periappendiceal inflammation. The appendix is said to be abnormal if it is distended or thickened and enlarges >5-7 mm. Meanwhile, periappendiceal inflammation includes abscesses, fluid collections, edema and phlegmon.^{21,22}

Periappendiceal inflammation or edema is seen as calcification of mesenteric fat ("dirty fat"), local fascia thickening, and increased soft tissue density in the right lower quadrant. Slow clinical symptom care (48-72 hours) can lead to phlegmon or abscesses, hence CT scans are recommended. Fecaliths are seen, but they do not indicate appendicitis. The arrowhead indication from cecum thickening is significant. CT-Scan disadvantages include iodinated-contrast-media allergies, patient discomfort from contrast media administration (particularly rectal contrast media), ionizing radiation exposure, cost, and pregnancy restrictions.²¹⁻²³

When compared to ultrasound, computed tomography (CT) scans are more accurate and are typically carried out in hospitals. When it comes to acute appendicitis, CT scans have a diagnostic accuracy rate that ranges from 93 to 98 percent. The findings of the CT scan are more likely to increase the certainty of the diagnosis than the findings of the ultrasound. When it comes to the diagnosis of acute appendicitis, the majority of the research literature is heading in the direction of the CT scan technique that is considered to be the most effective.²¹⁻²³

CONCLUSION

There are several examinations that can be done, for example US, plain radiology and CT scan. An ultrasound examination is an examination that can be carried out quickly and with sufficient accuracy to determine whether a person can be diagnosed as a patient with appendicitis.

REFERENCE

- [1] Baird DLH; Simillis C; Kontovounisios C; et al. Acute appendicitis. *BMJ*. 2017;357:1–6.
- [2] Stringer MD. Acute appendicitis. *J Paediatr Child Health*. 2017;53(11):1071–6.
- [3] Krzyzak M, Mulrooney SM. Acute Appendicitis Review: Background, Epidemiology, Diagnosis, and Treatment. *Cureus*. Juni 2020;12(6):e8562.
- [4] D'Souza N, Nugent K. Appendicitis. *BMJ Clin Evid*. Desember 2014;2014.
- [5] Almström M, Svensson JF, Svenningsson A, Hagel E, Wester T. Population-based cohort study on the epidemiology of acute appendicitis in children in Sweden in 1987–2013. *BJS open*. 2018;2(3):142–50.
- [6] Şenocak R, Kaymak Ş. Diagnostic accuracy of ultrasonography and scoring systems: The effects on the negative appendectomy rate and gender. *Turkish J Trauma Emerg Surg*. 2020;26(2):306–13.
- [7] Dişçi E, Peksöz R, Kaşali K, Bayar B. Diagnostic value of imaging methods in diagnosing acute appendicitis in comparison with leukocyte counts. *Ann Clin Anal Med*. 2021;12(4).
- [8] Snyder MJ, Guthrie M, Cagle S. Acute Appendicitis: Efficient Diagnosis and Management. *Am Fam Physician*. Juli 2018;98(1):25–33.
- [9] Moris D, Paulson EK, Pappas TN. Diagnosis and management of acute appendicitis in adults: a review. *JAMA*. 2021;326(22):2299–311.
- [10] Kim HY, Park JH, Lee SS, Lee WJ, Ko Y, Andersson RE, et al. CT in Differentiating Complicated From Uncomplicated Appendicitis: Presence of Any of 10 CT Features Versus Radiologists' Gestalt Assessment. *AJR Am J Roentgenol*. November 2019;213(5):W218–27.
- [11] Bourcier J-E, Gallard E, Redonnet J-P, Majourau M, Deshaie D, Bourgeois J-M, et al. Diagnostic performance of abdominal point of care ultrasound performed by an emergency physician in acute right iliac fossa pain. *Crit Ultrasound J*. November 2018;10(1):31.
- [12] Elbanna KY, Mohammed MF, Chahal T, Khosa F, Ali IT, Berger FH, et al. Dual-Energy CT in Differentiating Nonperforated Gangrenous Appendicitis From Uncomplicated Appendicitis. *AJR Am J Roentgenol*. Oktober 2018;211(4):776–82.
- [13] Corson-Knowles D, Russell FM. Clinical Ultrasound Is Safe and Highly Specific for Acute Appendicitis in Moderate to High Pre-test Probability Patients. *West J Emerg Med*. Mei 2018;19(3):460–4.
- [14] Gungor F, Kilic T, Akyol KC, Ayaz G, Cakir UC, Akcimen M, et al. Diagnostic Value and Effect of Bedside Ultrasound in Acute Appendicitis in the Emergency Department. *Acad Emerg Med Off J Soc Acad Emerg Med*. Mei 2017;24(5):578–86.
- [15] Mallin M, Craven P, Ockerse P, Steenblik J, Forbes B, Boehm K, et al. Diagnosis of appendicitis by bedside ultrasound in the ED. *Am J Emerg Med*. 2015;33(3):430–2.
- [16] Tan WJ, Acharyya S, Goh YC, Chan WH, Wong WK, Ooi LL, et al. Prospective comparison of the Alvarado score and CT scan in the evaluation of suspected appendicitis: a proposed algorithm to guide CT use. *J Am Coll Surg*. Februari 2015;220(2):218–24.
- [17] Park NH, Oh HE, Park HJ, Park JY. Ultrasonography of normal and abnormal appendix in children. *World J Radiol*. April 2011;3(4):85–91.
- [18] Hernanz-Schulman M. CT and US in the Diagnosis of Appendicitis: An Argument for CT. *Radiology* [Internet]. 10 Maret 2010;255(1):3–7. Tersedia pada: <https://doi.org/10.1148/radiol.09091211>
- [19] Hines JJ, Paek GK, Lee P, Wu L, Katz DS. Beyond appendicitis; radiologic review of unusual and rare pathology of the appendix. *Abdom Radiol* [Internet]. 2016;41(3):568–81. Tersedia pada: <https://doi.org/10.1007/s00261-015-0600-z>
- [20] Matthew Fields J, Davis J, Alsop C, Bates A, Au A, Adhikari S, et al. Accuracy of point-of-care ultrasonography

- for diagnosing acute appendicitis: a systematic review and meta-analysis. *Acad Emerg Med.* 2017;24(9):1124–36.
- [21] Evrimler S; Okumuser I; Unal N. Computed tomography (CT) findings of a diagnostic dilemma: atypically located acute appendicitis. *Pol J Radiol.* 2016;81:583–8.
- [22] Pooler BD, Lawrence EM, Pickhardt PJ. Alternative Diagnoses to Suspected Appendicitis at CT. *Radiology* [Internet]. 1 Desember 2012;265(3):733–42. Tersedia pada: <https://doi.org/10.1148/radiol.12120614>
- [23] Kim HY, Park JH, Lee YJ, Lee SS, Jeon J-J, Lee KH. Systematic Review and Meta-Analysis of CT Features for Differentiating Complicated and Uncomplicated Appendicitis. *Radiology* [Internet]. 27 November 2017;287(1):104–15. Tersedia pada: <https://doi.org/10.1148/radiol.2017171260>